


Patil J.D./ Deshpande A. Gems of Obstetrics and Gynecology with Homoeopathic Therapeutics

Extrait du livre

[Gems of Obstetrics and Gynecology with Homoeopathic Therapeutics](#)

de [Patil J.D./ Deshpande A.](#)

Éditeur : B. Jain



<http://www.editions-narayana.fr/b1603>

Sur notre [librairie en ligne](#) vous trouverez un grand choix de livres d'homéopathie en français, anglais et allemand.

Reproduction des extraits strictement interdite.

Narayana Verlag GmbH, Blumenplatz 2, D-79400 Kandern, Allemagne

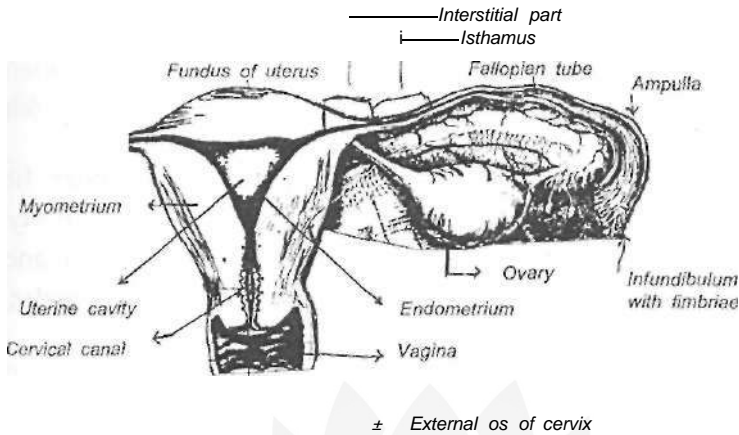
Tel. +33 9 7044 6488

Email info@editions-narayana.fr

<http://www.editions-narayana.fr>



Internal Female Genitalia



in relation with the cervix is divided into the anterior, posterior and lateral fornices. The anterior vaginal wall is nearly 7 cms. in length, whereas the posterior wall is 2 cms. more. It can be distended to a certain extent, but this depends upon the supporting muscles.

The Uterus

It is a thick, muscular, hollow organ. Its upper portion is somewhat broad and it gradually tapers towards the cervical canal. It is flattened antero-posteriorly and its size is approximately 7" x 2" x 1". The wall is 1 cm. thick and the length of the uterine cavity, from the fundus to the external os is nearly 3 inches. The different parts of the uterus are, fundus, body (corpus) and cervix. The lining of the uterus is known as endometrium. It is a specialized form of mucous membrane. The thickness of the endometrium varies according to the phases of menstrua-

Treatment:

1. Control convulsions : Phenobarbitone 10 mg./kg. body weight generally used.
2. Treat the cause.
3. Maintenance therapy.

JAUNDICE IN NEW BORN:

It is determined by the yellowish discolouration of the skin and mucous membranes due to excess of bilirubin. It is very common in the new borns.

Causes:

- 1) Physiological : Prematurity.
- 2) Pathological:
 - i. Feto-maternal blood incompatibility.
 - ii. Increased cell fragility.
 - iii. Neonatal septicemia.
 - iv. Defective conjugation of bilirubin.
 - v. Congenital obstruction of bile ducts.
 - vi. Syphilis, congenital.
 - vii. Cretinism.

STILL BIRTH:

It is defined as the birth of an infant after 28 weeks of pregnancy, and it does not breathe or show signs of life.

Gems of Obstetrics

pregnancy : Hypertension, nephritis, diabetes, syphilis, severe anemia, hyperpyrexia, etc.

- 4) Fetal or uterine congenital defects.
- 5) Rh incompatibility.
- 6) Fetal post maturity.
- 7) External version.
- 8) Cord around the neck.
- 9) Various drugs like Quinine, Morphine etc.

Signs and Symptoms:

- 1) Gradual retrogression of fundal height.
- 2) Uterus becomes flaccid.
- 3) Absence of fetal movements and heart sounds.

Diagnosis:

X ray:

- 1) Spaldings sign:
Over lapping of the flat skull bones.
- 2) Hyperflexion of the spine.
- 3) Crowding of rib shadow.

Ultrasonography:

- 1) Infection
- 2) Blood coagulation disorders.
- 3) Psychological upset.

Gems of Obstetrics

Natural contraception includes:

- Rhythm method.
- Prolonged lactation.
- Vaginal douching.
- Abstinence : This method though free of cost and with out any side effects has many disadvantages like:
 - i) Difficult to calculate, thus not useful during lactational amenorrhea and irregular menses.
 - ii) It requires compulsory abstinence and self control which may not always be succesful.
 - iii) Failure rate is high.

For male partner

Female partner

Temporary method

Coitus interruptus.

Safe period.

Condom.

Oral pills.

IUCD.

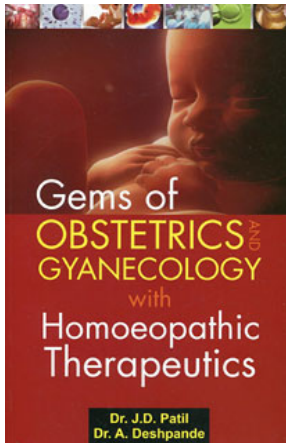
Spermicidal jellies and creams.

Cervical and vaginal diaphragm.

Permanent method

Vasectomy.

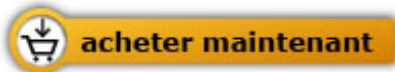Tubal occlusion operation.



Patil J.D./ Deshpande A.

[Gems of Obstetrics and Gyanecology
with Homoeopathic Therapeutics](#)

416 pages, broché
publication 2009



Plus de livres sur homéopathie, les médecines naturelles et un style de vie plus sain www.editions-narayana.fr