

# B. Jain

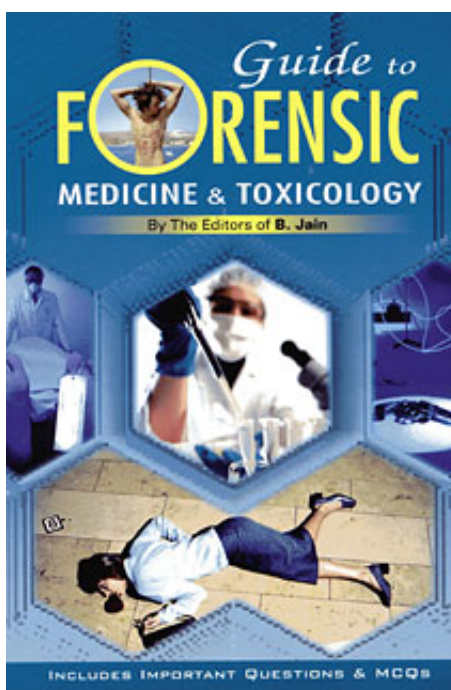
## Guide to Forensic Medicine & Toxicology

Extrait du livre

[Guide to Forensic Medicine & Toxicology](#)

de [B. Jain](#)

Éditeur : B. Jain



<http://www.editions-narayana.fr/b1118>

Sur notre [librairie en ligne](#) vous trouverez un grand choix de livres d'homéopathie en français, anglais et allemand.

Reproduction des extraits strictement interdite.

Narayana Verlag GmbH, Blumenplatz 2, D-79400 Kandern, Allemagne

Tel. +33 9 7044 6488

Email [info@editions-narayana.fr](mailto:info@editions-narayana.fr)

<http://www.editions-narayana.fr>



# 7

## REGIONAL INJURIES

### HEAD INJURY

The head is very vulnerable to injury, often with severe consequences. It is particularly susceptible to acceleration and deceleration and rotational forces because it is heavy in relation to its size, is freely mobile in three dimensions and occupies a relatively unstable position, being secured only by the neck muscles and ligaments.

#### Scalp Injuries

Scalp consists of several distinct layers; hairy skin, the sub-cutaneous fat and connective tissue layer, the galea or aponeurosis, a thin layer of connective tissue and finally the periosteum of the skull.

The scalp is susceptible to all types of injury, particularly laceration as it is readily crushed and split against the underlying bone. Such lacerations are often linear due to the convexity of the underlying skull. The scalp often swells markedly due to oedema or haematoma formation due to bruising above or below the galeal layer. Dense hair may mask scalp injuries.

#### Skull Fracture

The adult skull is formed by the fusion of several plates of bone, which become knitted solidly together along the cranial sutures. Each skull bone consists of a thick outer layer or table of bone, the spongy, diploe and the thinner inner table. The inner skull table is lined by thick fibrous adherent membranes. A small space lies between the inner surface of the dura and the thin membranous arachnoid mater, which covers the surface of the brain.

The solid skull is deformed by localised impact, which may damage the cranial contents even when the skull does not fracture. If the force and deformation is excessive the skull fracture is at or near the site of impact; uncomplicated skull fractures themselves are rarely lethal - it is the associated intra-cranial damage which is lethal. A fracture indicates that substantial force has been applied to the head, which is likely to have damaged the cranial contents. Skull fractures may occur with no associated

neurological damage and conversely, fatal injury to membranes blood vessels and the brain may occur without overlying fracture.

Force required to cause fracture is very variable and depends on the thickness of the hair, scalp and skull, which part of the skull is struck, the direction of impact and other imponderables.

### *Types of Skull Fracture*

Linear - from the point of impact along lines of anatomical weakness.

Frontal often radiates into the anterior cranial fossa.

Temporal fracture (e.g. blow to the side of head) often radiates into middle cranial fossa.

Occipital fracture (e.g. backwards fall) often radiates into posterior cranial fossa.

Radiating - outwards from the point of impact.

Spider's web - radiating lines connected by concentric fracture rings.

Depressed - where fragments are driven inwards.

Hinge - passing across the base of the skull (motorcyclist or blow to chin)

Ring - encircling the hole through which the spinal cord passes downwards. Due to a fall onto the feet or onto the top of the head.

Counter-coup - a backwards fall, striking the back of the head (coup) may also cause fracture of the thin layer of bone over the roof of the orbits opposite the point of impact due to suction forces transmitted through the brain tissue.

### **Intra Cranial Haemorrhage**

The dural and arachnoid membranes and their associated blood vessels are readily torn by impact of fractured bone fragments. The process of haemorrhage results in the formation of a localised accumulation of blood, or haematoma.

### *Extradural Haemorrhage (EDH)*

A blow to the temple often fractures the thin temporal bone and tears the middle meningeal artery as it passes upwards within a groove between the inner skull table and the dura. In 15% of cases no fracture is identified. Arterial bleeding strips the dura off the inner skull table to form a haematoma, which acts as a space-occupying lesion (SOL). This accumulation can be immediate or delayed. EDH is easily overlooked as mild concussion is followed by a lucid interval before neurological symptoms and coma develop many hours later when the enlarging haematoma begins to exert pressure on the brain. Amenable to surgical decompression in early stages.

### *Subdural Haemorrhage (SDH)*

More common than EDH.

Not usually associated with skull fracture. Sudden jerking or rotation of the head causes movement of the brain relative to the dura. This shears and tears the small veins which bridge across the gap between the dura and cortical surface of the brain. The leaking blood accumulates over several hours and usually tracks extensively as a thin film over the surface of the brain. SDH is especially common in the elderly, children and alcoholics (frequent unprotected falls and prolonged bleeding times). A small, self-limiting SDH may remain asymptomatic and be an incidental finding at autopsy.

### *Subarachnoid Haemorrhage (SAH)*

May be natural, due to rupture of a dilated blood vessel or traumatic. SAH is highly irritant to the brain stem and is usually rapidly fatal. Traumatic SAH may be usually associated with contusion or laceration of the brain surface.

Rarely SAH is due to a kick or blow to the side of the neck which stretches and ruptures the vertebral artery as it enters the cranial cavity. This phenomenon is called traumatic basal SAH and is most often due to a blow to the side of the chin or jaw in a fight. The degree of force required to cause death in this way is less than would be reasonably expected, resulting in prosecution for culpable homicide, rather than murder.

### *Intracerebral Haemorrhage*

May be natural, due to spontaneous rupture and is likely to occur at a time of stress or excitement when the blood pressure is acutely elevated.

May be traumatic, due to extension of haemorrhage from surface contusions deep into the substance of the brain. Traumatic intracerebral haemorrhage may also be the result of rupture of small blood vessels deep within the brain due to shearing stress.

## **Brain Injury**

The brain consists of the cerebrum, cerebellum and brain stem. The cerebrum is the largest component and consists of the right and left cerebral hemispheres, each of which has frontal, parietal, temporal and occipital lobes. The cerebral hemispheres are separated at the midline by a vertical fold of dura called the falx. The occipital lobes sit above two further horizontal folds of dura, which separate them from the cerebellum below. Below the cerebral hemispheres and in front of the cerebellar hemispheres lies the brain stem. Although small this houses the vital nerve centers controlling consciousness, breathing, and heart function. The brain stem passes down through the only exit from the cranial cavity to become the spinal cord.

Minor jarring of the brain causes concussion, a clinical state of transient loss of consciousness due to temporary nerve cell dysfunction. Retrograde amnesia is common. Bruising on the surface of the brain is called cerebral contusion, and is of two types:

1. "Coup type" contusion: A blow to the head when it is free to move accelerates the head and causes cerebral contusion at the point of impact. Scalp injury is likely to occur at the point of primary impact. Contusion or laceration of the brain surface often occurs at the site of a fracture, especially if it is depressed.
2. "Counter - coup type" contusion: When the falling head strikes the ground it decelerates abruptly while the semi fluid brain continues moving towards the point of impact. This causes more severe contusions in the area diametrically opposite the point of impact. Such "Counter-coup" contusions occur where the brain glides over the irregular, jagged contours of the skull interior and are usually more severe than the corresponding coup type contusions. Negative suction pressures, which develop opposite the point of impact, are also involved in their causation. Greater counter - coup force may also lacerate the brain surface. In this way a backward fall causes counter - coup contusions at the front of the brain. Similarly, a fall onto one side of the head causes counter - coup contusions at the opposite side of the brain, this pattern is useful in distinguishing at autopsy head injuries due to falls from those due to blows. However, a forward fall does not cause counter - coup contusions over the back of the brain due to interior of the skull being smooth at this point.

Severe brain injury may still have occurred even in the absence of any associated scalp injury, skull fracture, intra-cranial haemorrhage or cerebral contusions.

Rotation and acceleration/deceleration injury are more damaging to the brain than direct impact against the fixed, immobile head. This is because rotation causes the layers of brain tissue to glide over each other like a pack of cards, causing shearing of the delicate connection between the nerve fibres. Widespread subtle microscopic nerve fibre injury of this type is common in road traffic accidents, due to the frequency of severe rotational impact and deceleration. Such microscopic damage to nerve fibres is generalized and not amenable to surgery. There may be nothing to see on the surface of the brain or on slicing at autopsy. Diagnosis usually requires expert neuropathological examination using special stains to demonstrate subtle microscopic damage to nerve fibres. Diffuse axonal injury is often associated with brain swelling. Shearing or gliding injury may also rupture

small blood vessels deep within the white matter of the brain causing numerous deep small haemorrhages.

## **Complications of Head Injury**

Intracranial haemorrhage. These complications create a space occupying lesion.

Brain swelling is a common and frequently fatal complication of head injury, which may develop within minutes, or hours of injury. Swelling may accompany diffuse axonal injury or a space-occupying lesion such as an intra-cranial haematoma. In children brain swelling may be the only identifiable feature of head injury. A swollen brain is heavy with visible enlargement of the surface convolutions at the expense of obliteration of the intervening gaps and compression of the fluid filled cavities (ventricles) deep within the brain. Emergency neuro-surgical procedures frequently attempted include drainage of an ICH or removal of severely damaged brain tissue in an attempt to reduce intra cranial pressure. Brain swelling is frequently a fatal complication even after such measures.

The skull is a rigid bony compartment with only one exit. Severe brain swelling as a large intra cranial haemorrhage may cause displacement of the brain tissue downwards the foramen magnum. The inner lower edge of a cerebral hemisphere become compressed against the sharp edges of the dural folds or can be actually forced out under the free edge of the dura (causing uncal herniation). The cerebellum is similarly squashed down into the foramen magnum. (Causing tonsillar coning and necrosis). Pressure on the brain stem and secondary brain stem haemorrhage may occur and are fatal complications of raised ICP.

Meningitis and brain abscess: particularly common after penetrating head injury and after fracture, which disrupt the nasal and frontal air sinuses.

Post traumatic epilepsy : healing and scarring of the meninges and brain surface may be focus of later epileptic fits.

## **FACIAL INJURY**

Common in accidents, assault by punching, kicking or blunt weapon. The fragile facial bones are susceptible to fracture. Bleeding from the nose, mouth and sinuses may obstruct the air passages.

## **NECK INJURY**

A very vulnerable area with easy access to vital structures such as the trachea, large vessels. Incision, stabs, blows and manual pressure are very dangerous in this area. The cervical spine and spinal cord are also vulnerable, sensitive nervous connections and reflexes can be stimulated with fatal results (vagal reflex) .

small blood vessels deep within the white matter of the brain causing numerous deep small haemorrhages.

### **Complications of Head Injury**

Intracranial haemorrhage. These complications create a space occupying lesion.

Brain swelling is a common and frequently fatal complication of head injury, which may develop within minutes, or hours of injury. Swelling may accompany diffuse axonal injury or a space-occupying lesion such as an intra-cranial haematoma. In children brain swelling may be the only identifiable feature of head injury. A swollen brain is heavy with visible enlargement of the surface convolutions at the expense of obliteration of the intervening gaps and compression of the fluid filled cavities (ventricles) deep within the brain. Emergency neuro- surgical procedures frequently attempted include drainage of an ICH or removal of severely damaged brain tissue in an attempt to reduce intra cranial pressure. Brain swelling is frequently a fatal complication even after such measures.

The skull is a rigid bony compartment with only one exit. Severe brain swelling as a large intra cranial haemorrhage may cause displacement of the brain tissue downwards the foramen magnum. The inner lower edge of a cerebral hemisphere become compressed against the sharp edges of the dural folds or can be actually forced out under the free edge of the dura (causing uncal herniation). The cerebellum is similarly squashed down into the foramen magnum. (Causing tonsillar coning and necrosis). Pressure on the brain stem and secondary brain stem haemorrhage may occur and are fatal complications of raised ICP.

Meningitis and brain abscess: particularly common after penetrating head injury and after fracture, which disrupt the nasal and frontal air sinuses.

Post traumatic epilepsy : healing and scarring of the meninges and brain surface may be focus of later epileptic fits.

### **FACIAL INJURY**

Common in accidents, assault by punching, kicking or blunt weapon. The fragile facial bones are susceptible to fracture. Bleeding from the nose, mouth and sinuses may obstruct the air passages.

### **NECK INJURY**

A very vulnerable area with easy access to vital structures such as the trachea, large vessels. Incision, stabs, blows and manual pressure are very dangerous in this area. The cervical spine and spinal cord are also vulnerable, sensitive nervous connections and reflexes can be stimulated with fatal results (vagal reflex).

## MEDICO-LEGAL ASPECTS OF WOUNDS

### Injury

Any harm whatever illegally caused to any person in body, mind, reputation or property (section 44 IPC).

### Hurt

It means bodily pain, disease or infirmity caused to any person (section 139 IPC)

### Grievous Injury

It is defined as an injury, which result in a permanent damage or loss of a part of the body, or it incapacitates a man from his normal work for more than 20 days. Under section 320 IPC it consists of any one or more of the following conditions:

1. Emasculation: Loss of musculanity of a person due to either direct damage to the testes or injuries involving the spinal cord.
2. Permanent privation of sight of one or both eyes.
3. Permanent privation of hearing of one or both ears.
4. Privation of any member or joint.
5. Destruction or permanent impairment of the power of any member or joint.
6. Permanent disfigurement of the head or face.
7. Fracture or dislocation of a bone or tooth.
8. Any injury, which endangers life or causes, the sufferer severe physical pain or renders him unable to follow his ordinary pursuits during a space for 20 days.

A mere stay of more than 20 days in the hospital does not constitute a grievous injury. It has to be proved that the victim was in severe bodily pain or was unable to perform any normal pursuits.

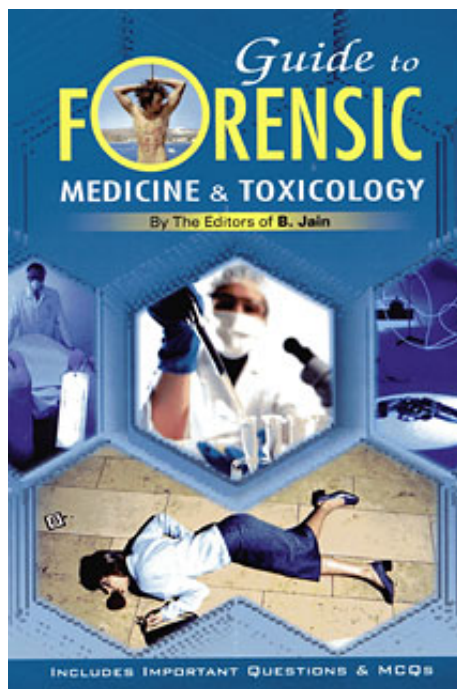
**Punishment for voluntarily causing hurt:** Imprisonment upto one year, or with fine upto one thousand rupees or both.

**Voluntarily causing grievous hurt by dangerous weapons or means:** Imprisonment for a term upto ten years and also fine. (Section 326, IPC)

**Punishment for voluntarily causing grievous hurt:** Imprisonment for a term extending to seven years and also fine. (Section 35, IPC)

**Voluntarily causing hurt by dangerous weapons or means:** Imprisonment for a term upto three years or with fine or both. (Section 324, IPC)

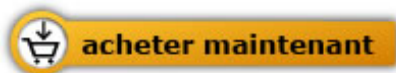



B. Jain

[Guide to Forensic Medicine & Toxicology](#)

224 pages, broché  
publication 2004



Plus de livres sur homéopathie, les médecines naturelles et un style de vie plus sain  
[www.editions-narayana.fr](http://www.editions-narayana.fr)