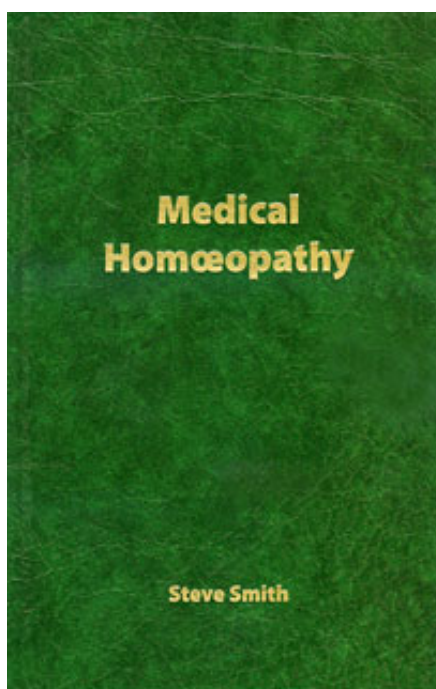


Steve Smith

Medical Homoeopathy

Extrait du livre
[Medical Homoeopathy](#)
de [Steve Smith](#)
Éditeur : Winter Press



<http://www.editions-narayana.fr/b4643>

Sur notre [librairie en ligne](#) vous trouverez un grand choix de livres d'homéopathie en français, anglais et allemand.

Reproduction des extraits strictement interdite.
Narayana Verlag GmbH, Blumenplatz 2, D-79400 Kandern, Allemagne
Tel. +33 9 7044 6488
Email info@editions-narayana.fr
<http://www.editions-narayana.fr>



THE NERVOUS SYSTEM

The nervous system, frankly, is a difficult area of anatomy & physiology to study. It is littered with possibilities for confusion and indecision regarding pathology. Most practitioners get plenty of patients who have diseases related to the nervous system, so it's an area where you need to try and establish some clarity.

The human nervous system is responsible for sending, receiving, and processing nerve impulses... as if you couldn't guess that. All of the body's muscles and organs rely upon these nerve impulses to function.

Three systems work together to carry out the mission of the nervous system: the central, the peripheral, and the autonomic nervous systems.

THE CENTRAL NERVOUS SYSTEM

Is responsible for issuing nerve impulses and analysing sensory data, and includes the brain and spinal cord.

THE PERIPHERAL NERVOUS SYSTEM

Carries nerve impulses to and from the body's many structures, and includes the many craniospinal nerves that branch off the brain and spinal cord.

THE AUTONOMIC NERVOUS SYSTEM

This comprises the sympathetic and parasympathetic systems and is responsible for regulating and coordinating the functions of vital structures in the body, such as heart rate, perspiration, salivation, and intestinal movements.

Definitions For This Page
Autonomic means involuntary.
The Sympathetic Nervous System is the part of the autonomic nervous system which has an 'excitatory effect' – increasing blood flow to the limbs, opening airways in the lungs, etc.
The Parasympathetic System has the opposite effect- a 'depressive effect', reducing heart rate etc.

The brain is the primary component of the nervous system, occupying the cranial cavity. Without its outermost protective membrane, the dura mater, the brain weighs an average of three pounds, comprising about 97% of the entire central nervous system. The brain is connected to the upper end of the spinal cord (which connects through the foramen magnum of the skull) and is responsible for issuing nerve impulses, processing nerve impulse data, and engaging in the higher order thought processes. The brain is divided into three parts: the large cerebrum, the smaller cerebellum, and the brainstem leading to the spinal cord. The brainstem is also descriptively divided into the medulla oblongata, the midbrain, and the pons.

In humans the brain is a mass of pinkish-grey tissue composed of about 100 billion nerve cells, each linked to another and together responsible for the control of all mental functions.

The brain, in addition to nerve cells (neurones), contains glial cells (supporting cells), blood vessels, and secretory organs. The brain is the control centre for movement, sleep, hunger, thirst, and virtually every other vital activity necessary to survival. All human emotions, including love, hate, fear, anger, elation, and sadness, are controlled by the brain. It also receives and interprets the countless signals that are sent to it from other parts of the body and from the external environment.

ANATOMY AND COMPOSITION

From the outside the brain appears as three distinct but connected parts: the cerebrum, the cerebellum, and the brain stem. The term brain stem usually refers to all the structures lying between the cerebrum and the spinal cord.

In addition, although the brain is well protected by the cranium, three membranes called meninges cover it. The outer one, the dura mater, is tough and shiny. The middle membrane, the arachnoid layer, encloses the brain loosely and does not slip down into the brain's convolutions, or ridges. The inner membrane, the pia mater, consists mainly of small blood vessels that adhere to the surface of the brain.

CEREBRUM

The cerebrum is the largest part of the human brain, making up approximately 85 percent of the brain's weight, its large surface area and intricate development account for the allegedly superior intelligence of humans, compared to other animals.

The cerebrum is divided by a longitudinal fissure into right and left, mirror-image hemispheres. The corpus callosum is the slab of white nerve fibres that connects these two cerebral hemispheres and transfers important information from one side of the brain to the other.

You may hear of disturbances to the pressure of the Cerebrospinal fluid (CSF). It is the CSF which circulates within these cerebral ventricles and around the spinal cord and serves to protect the inner part of the brain from varying pressures. It also transports chemical substances within the nervous system.

CEREBELLUM

The cerebellum lies in the posterior of the cranium, underneath the cerebral hemispheres. Like the cerebrum, it is made up of grey, unmyelinated cells on the exterior and white, myelinated cells in the interior. It is composed of two multi-ridged hemispheres that are connected by white fibres called the vermis.

The cerebellum is linked with the midbrain by the superior (top) peduncle, with the pons by the middle peduncle, and with the medulla by the inferior (bottom) peduncle. This is just for your information - what you really need to know is what it does, which is as follows...

The cerebellum is essential to the control of movement of the human body in space. It acts as a reflex centre for the coordination and precise maintenance of equilibrium. Voluntary muscle tone - as related to posture, balance, and equilibrium - is similarly controlled by this vital part of the brain. Thus, all motor activity, from hitting a cricket ball to fingering a violin, depends on the cerebellum.

BRAIN STEM

The brain stem is divided into several components, each of which is described below.

THALAMUS

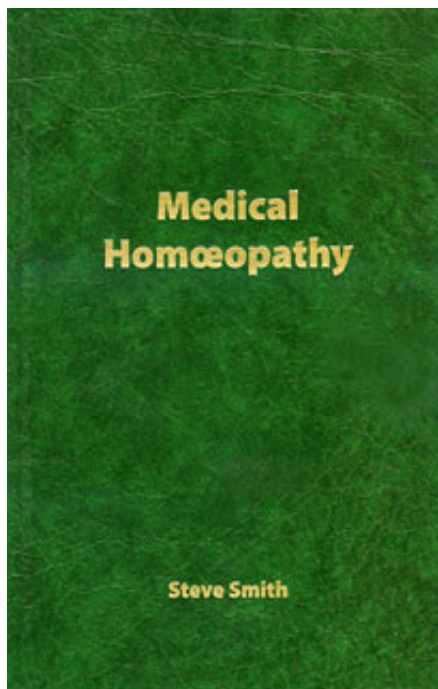
This part of the forebrain consists of two rounded masses of grey tissue lying within the very middle of the brain, between the two hemispheres. It is the crucial relay station for incoming sensory signals and outgoing motor signals passing to and from the cerebral cortex. All sensory input to the brain, except that of the sense of smell, connects to individual nerve cells of the thalamus.

HYPOTHALAMUS

The hypothalamus lies just below the thalamus on the midline at the base of the brain. It is made up of distinct areas and nuclei. The hypothalamus regulates or is involved directly in the control of many of the body's vital activities and drives those that are necessary for survival: eating, drinking, temperature regulation, sleep, emotional behaviour and sexual activity.

MIDBRAIN

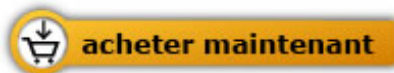The mesencephalon is composed of three parts. The first consists of the cerebral peduncles, fibre systems that conduct impulses to and from the cerebrum. The second is the corpora quadrigemina, four bodies that relay signals through the visual and auditory pathways. The third is a central canal, called the aqueduct of Sylvius, around which is located grey matter that is important in pain and also possibly in addictive states.



Steve Smith

[Medical Homoeopathy](#)

288 pages, relié
publication 2007



Plus de livres sur homéopathie, les médecines naturelles et un style de vie plus sain

www.editions-narayana.fr