


John R. Kippax Diseases of the Skin

Reading excerpt

[Diseases of the Skin](#)

of [John R. Kippax](#)

Publisher: B. Jain



<http://www.narayana-verlag.com/b1387>

In the [Narayana webshop](#) you can find all english books on homeopathy, alternative medicine and a healthy life.

Copying excerpts is not permitted.

Narayana Verlag GmbH, Blumenplatz 2, D-79400 Kandern, Germany

Tel. +49 7626 9749 700

Email info@narayana-verlag.com

<http://www.narayana-verlag.com>



DISEASES OF THE SKIN.

I»A.S.T I.

GENERAL OBSERVATIONS.

SECTION I. THE ANATOMY AND PATHOLOGY OF THE SKIN.

The skin is a flexible membrane which invests the body, and joins the mucous surfaces at the various orifices. Its office is to protect the underlying structures from harm, to give shape and symmetry to the human form, to act as a partial respirator, and to perform the important functions of secretion, absorption, and tactile perception. Upon its surface are found numerous elevations, furrows and depressions. The larger elevations, which take the form of lines or wrinkles, are particularly well defined on the palm of the hand and sole of the foot. The smaller elevations are found upon almost all regions of the body, and are caused by the prominence of the papillae. The furrows correspond to the larger elevations and lie between them. The minute depressions or pores, are the orifices of glandular ducts and of hair-follicles.

Like most tissues of the body the skin is composed of fibres and cells.

The fibres are of two kinds: white fibrous tissue, and yellow elastic fibres. The white fibres give to the skin strength, and the yellow, elasticity.

The cells are of four kinds, namely, the cells of the rete or stratum malpighii; secondly, those of the stratum granulosum; thirdly, those of the stratum lucidum; and fourthly, those of the stratum corneum.

The cells of the stratum malpighii are nucleated, polygonal in form, and rich in protoplasm. When isolated they resemble in outline a chestnut burr, and hence are termed "prickle cells.

The cells of the stratum granulosum are spindle-shaped, have a distinct, clear nucleus, and are arranged in two rows.

Those of the stratum lucidum are flattened, indistinctly striated, and contain a staff-shaped, or flattened nucleus. They are formed from the cells of the stratum granulosum, and are arranged in three rows.

And lastly, those of the stratum corneum, or horny epidermis, are flattened, have no nucleus, and are usually larger than the other cells.

These six elements, the two kinds of fibres, and the four sorts of-cells, constitute the main part of the structure of the skin.

Anatomically, the skin maybe divided into two main layers, termed respectively the *corium* and *epidermis*. Again, these two may be subdivided; the former, into the reticular and papillary layers, and the latter

complex cases, where the unaided eye is unable to solve the problem, a microscope provided with a fifth and half inch objective, may be used with profit.

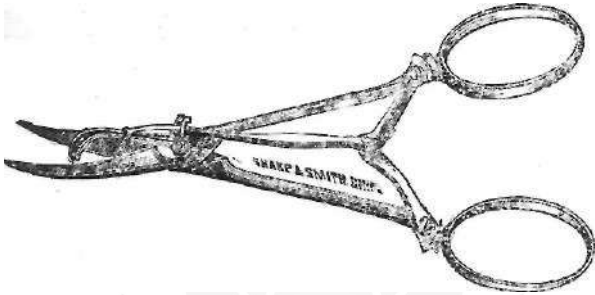


FIG. 3. SKIN GRAFTING SCISSORS.

When necessary, as in affections of the beard or scalp, one or more hairs may be secured for examination by extraction with a pair of epilating forceps, (Fig. 12.) Small slices of other parts to be examined can be easily obtained by the use of the skin-grafting scissors, (Fig. 3.) or, if still thinner sections are needed, the cutisector (Fig. 4.) may be employed.

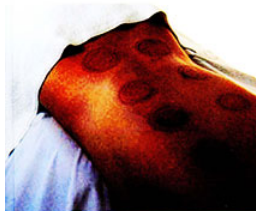

FIG. 4. THE CUTISECTOR.

The temperature of parts, if desired, is readily taken by Seguin's surface thermometer. (Fig. 5.)

A Handbook of
DISEASES OF THE SKIN
and their
Homeopathic Treatment

John R. Kippax, M.D.



Fifth Edition, Revised and Enlarged

John R. Kippax

[Diseases of the Skin](#)

294 pages, pb
publication 2006



order

More books on homeopathy, alternative medicine and a
healthy life www.narayana-verlag.com