



# Narayana Verlag Spectrum of Homeopathy 2015-3, Diagnosis Borreliosis - Mängelexemplar

Reading excerpt

[Spectrum of Homeopathy 2015-3, Diagnosis Borreliosis - Mängelexemplar](#)  
of [Narayana Verlag](#)

Publisher: Narayana Verlag



<https://www.narayana-verlag.com/b30382>

In the [Narayana webshop](#) you can find all english books on homeopathy, alternative medicine and a healthy life.

Copyright:

Â Narayana Verlag GmbH, Blumenplatz 2, D-79400 Kandern, Germany

Tel. +49 7626 9749 700

Email [info@narayana-verlag.com](mailto:info@narayana-verlag.com)

<https://www.narayana-verlag.com>

[Narayana Verlag](#) is a publishing company for books on homeopathy, alternative medicine and a healthy life. We publish books of top-class and innovative authors like [Rosina Sonnenschmidt](#), [Rajan Sankaran](#), [George Viithoukas](#), [Douglas M. Borland](#), [Jan Scholten](#), [Frans Kusse](#), [Massimo Mangialavori](#), [Kate Birch](#), [Vaikunthanath Das Kaviraj](#), [Sandra Perko](#), [Ulrich Welte](#), [Patricia Le Roux](#), [Samuel Hahnemann](#), [Mohinder Singh Jus](#), [Dinesh Chauhan](#).

[Narayana Verlag](#) organises [Homeopathy Seminars](#). Worldwide known speakers like [Rosina Sonnenschmidt](#), [Massimo Mangialavori](#), [Jan Scholten](#), [Rajan Sankaran](#) & [Louis Klein](#) inspire up to 300 participants.

# SPECTRUM OF HOMEOPATHY

NO. 3 | 2015

18 € | 24 \$  
ISSN 1869-3091



JÜRGEN HANSEL  
MARCO RIEFER  
CHRISTINA ARI  
HEIDI BRAND  
ULRICH WELTE  
DEBORAH COLLINS  
ALEX LEUPEN  
ANNEMIEK KLITSIE  
HANS EBERLE  
FRIEDRICH RITZER  
DANIÈLE JOULIN  
GUY PAYEN  
RAJAN SANKARAN  
RISHI VYAS  
ANNE SCHADDE  
JÜRGEN FAUST



## DIAGNOSIS **BORRELIOSIS**

  
Narayana Verlag

# SPECTRUM OF HOMEOPATHY

NO. 3 | 2015

18 € | 24 \$  
ISSN 1869-3091

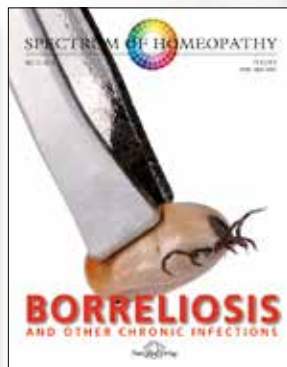
JÜRGEN HANSEL  
MARCO RIEFER  
CHRISTINA ARI  
HEIDI BRAND  
ULRICH WELTE  
DEBORAH COLLINS  
ALEX LEUPEN  
ANNEMIEK KLITSIE  
HANS EBERLE  
FRIEDRICH RITZER  
DANIÈLE JOULIN  
GUY PAYEN  
RAJAN SANKARAN  
RISHI VYAS  
ANNE SCHADDE  
JÜRGEN FAUST

## DIAGNOSIS **BORRELIOSIS**

Narayana Verlag



Order this issue (€ 18 / \$ 24)



Order all issues 2015 (€ 45 / \$ 59)

# EDITORIAL

## Dear readers,

This issue of SPECTRUM is devoted to the topic of Lyme disease or borreliosis, which is not so much a specific illness as a gray area of medical diagnosis. On the one hand, there are multiple manifestations of borreliosis infection, on the other hand, the diagnostic power of the serology is often overrated. In the overview article at the beginning of this issue, we examine this dilemma more closely. The classic example is the patient with diffuse joint pain, chronic fatigue and IgG antibodies for borreliosis. Is this Lyme disease or is it fibromyalgia with evidence of antibodies trace following contact with the infectious agent? Should this be treated with antibiotics?

The clinical postulate of conventional medicine, “a diagnosis is needed in order to treat,” does not always apply to us homeopaths – we can also treat very effectively in the gray zone of an uncertain diagnosis. The authors in this issue demonstrate how this works with the syndrome mentioned above: arthralgia, exhaustion, and a positive blood test for borreliosis. Seven contributions deal with such cases, in which all patients came to the homeopathic practice with a diagnosis of borreliosis.

It was striking how patients have so many things in common beyond the initial diagnosis of borreliosis. The authors, although working with different homeopathic approaches, noticed very similar psychodynamics in these patients: they tend to be self-sacrificing, are easily exploited, so becoming victims and outsiders. Ulrich Welte derives this theme from the Ericales order, using Scholten’s Plant theory, and shows why *Ledum* and other plants of this order are such good borreliosis remedies. Three other cases, from Alex Leupen, Annemiek Klitsie, and Deborah Collins demonstrate the use of remedies from the Ericaceae family, with or without the use of the *Borrelia* nosode. Marco Riefer identifies the theme of victims who are sucked and sapped in quite different groups and natural kingdoms. At the sensation level, one can feel as “sucked dry as a lump of chewing gum,” as Jürgen Faust demonstrates in his case of *Strophanthus* and the typical reaction patterns of the Dogbane family. Together with Anne Schadde’s depiction of the Poaceae family, using an example of chronic borreliosis, and Welte’s order of Ericales, this edition of SPECTRUM therefore expands its systematic coverage of the materia medica with three new remedy groups from the Plant kingdom.

We also have information on two more new remedies: Heidi Brand has successfully used the freshwater alga *Chara intermedia* – of which

she made the proving – in a case of “Post-Treatment Lyme Disease Syndrome” (PTLDS), in which the typical victim theme again surfaces. As in most other case histories, her homeopathic treatment heals not just the physical symptoms but also leads to a deep transformation in the underlying psychodynamics. Hans Eberle and Friedrich Ritzer also recognized the symptoms from their own remedy proving in the illness of a borreliosis patient. This example introduces us to the new homeopathic remedy *Adalia bipunctata*, the two-spot ladybird. In the second case, the two authors explain how they identified *Thuja occidentalis* using Scholten’s analysis rather than via the well-known remedy picture. Danièle Joulin and Guy Payen took the same route to the remedy. They treat the syndrome characterized as “chronic borreliosis” with the nosode *Borrelia burgdorferi* in addition to the simillimum. The nosode is – together with *Ledum* – a key element in the treatment approach used by Christina Ari. In her contribution, she is concerned not with the diagnostic gray zone of chronic borreliosis but rather with the distinctive skin symptoms seen in the initial phase of the illness, which she treats homeopathically when the patient has declined antibiotics. According to Ari, the susceptibility to borreliosis can frequently be traced to poor living conditions, which weaken patients and predispose them to disease.

In proven, clear cases of borreliosis, antibiotic treatment is medically indicated and only the patient can then decline this approach. Yet, in the ever more frequent cases from the gray zone, we consider homeopathic treatment the better choice.

## Christa Gebhardt & Dr Jürgen Hansel

Chief editors





Page 82

Vital sensation of the Dogbane family: the polarity between tension and slackness.



Page 10

Typical psychodynamics: the relationship between feeling victimized and borreliosis.



Page 4

Current state of knowledge: epidemiology, diagnosis, and treatment of Lyme borreliosis.



Page 38

Practical experience: the Ericales as tried-and-tested remedies for borreliosis.



Page 48

Rhododendron contains diterpene grayanotoxins, which affect the nervous system, causing memory loss, dizziness, and hypotension.

# CONTENTS

## EDITORIAL:

### Diagnosis: BORRELIOSIS

Page 1

Jürgen Hansel

#### HARD AND SOFT FACTS:

Overview of borreliosis – the many facets of a diagnosis

Page 4

#### FLAG

Page 7

Marco Riefer

#### EXPLOITED, DEFENSELESS, SUCKED DRY:

Parasitic aspects in the lives of patients suffering from Borreliosis

Page 10

Christina Ari

UNSTABLE ORDER: Ledum and borreliosis nosodes as acute remedies

Page 22

Heidi Brand

#### I'M STUCK WITH EVERYTHING:

Chara intermedia and pollution with borreliosis

Page 30

Ulrich Welte

#### SELF-SACRIFICE AND EXPLOITATION:

Ericales are first-choice remedies for Lyme borreliosis

Page 38

Deborah Collins

GOING CRAZY: On the usefulness of remedies from the Ericaceae family in the treatment of Lyme disease

Page 48

Alex Leupen / Annemiek Klitsie

#### LOSS OF SELF AND SLEEPINESS:

Cooperation between the Borelia nosode and remedies from the Ericaceae family

Page 52

Hans Eberle / Friedrich Ritzer

CLINICAL FOCUS: Adalia bipunctata and Thuja for chronic borreliosis

Page 56

Danièle Joulin / Guy Payen

#### LOVE, REVOLUTION, AND RESIGNATION:

Dysprosium sulfuricum and Germanium for borreliosis with depression

Page 62

Rajan Sankaran / Rishi Vyas

TENSE OR RELAXED: The characteristic sensation of Rhus toxicodendron

Page 68

Anne Schadde

#### STAGGERING WITH EXHAUSTION:

Lolium temulentum, grasses, and chronic overload syndrome

Page 76

Jürgen Faust

#### A PIECE OF CHEWING GUM SUCKED OUT:

Strophanthus sarmentosus and the vital sensation of the Apocynaceae

Page 82

## PANORAMA

### BOOKS

Page 90

Syphilis by Jeremy Sherr

Acids in Homeopathy by Massimo Mangialavori

### HOMEOPATHY IN SOUTH AFRICA

Page 93

#### Travelogue:

“Natural beauty with a wealth of medicinal plants”

#### Interview with Ashley Ross:

“We want to share our experience with the homeopathic community worldwide.”

### NEWS

Page 99

#### Help for refugees:

Homeopaths without Borders – a new project for the refugees in Germany



# UNSTABLE ORDER

Ledum and the borreliosis nosode as acute remedies

AUTHOR | Christina Ari

**SUMMARY:** using three cases in which patients decline antibiotics, the author describes homeopathic treatment in the early stages of borreliosis. Before constitutional treatment, Ledum and the borreliosis nosode are used. In all three cases, the borreliosis coincides with deep uncertainty in the patient's life. In the author's experience, the liability to borreliosis infection is increased if the person is feeling generally unstable.

**KEYWORDS:** Acidum phosphoricum, Apis, arthralgia, borreliosis, borreliosis nosode, Calcium silicatum, lymphadenosis benigna cutis, erythema migrans, Ledum, Silicea, tick bite, Tuberculinum, Zincum muriaticum

## PERSONAL ENCOUNTERS WITH IXODES RICINUS, THE CASTOR BEAN TICK

In the 1950s, when I was still a child, I shared a bedroom with my grandmother. I still clearly remember, as if it was yesterday, seeing these strange, black, round creatures of varying sizes in the varicose veins at the back of her knees when she got undressed for bed.

"What are those, granny?" I asked in surprise.

"They're just ticks," she replied casually. "They suck my blood to survive!"

"Why don't you take them off?"

"There's no need. They fall off when they've had enough."

My grandmother, who was born in 1886 as the ninth of fourteen children and who grew up in very poor circumstances, had no idea that ticks can transmit disease. She was healthy all her life and died at the age of 94, shortly after fracturing her radius. I often remember this conversation – it

has remained an inspiration to me and has strengthened my confidence in a better world, giving me strength and optimism.

## THE DISCOVERY OF THE MONSTER TICK

In the 1970s, when I was a student, I was destined to encounter the castor bean tick in a very different way. The vaccination campaign for tick-borne encephalitis was just taking off and Lyme borreliosis had recently been recognized as a discrete disease. At that time, there was scarcely an alley in the center of Vienna without at least one poster with an oversized and menacingly monstrous picture of a tick! The effect was to announce "red alert!" justified by a general hysteria about ticks in the consciousness of modern civilization.

So, who was to be trusted, this dreadful monster or my grandmother?

Ever since I was a small child, I had repeatedly had contact with ticks but without ever feeling afraid of an infection. In 1990, when I was hopelessly swamped with work and unable to cope, as I had transferred from Vienna to the countryside, where I opened a private medical practice, and when I was also in the throes of a divorce, I fell ill with a borreliosis infection. Erythema developed on my right wrist, accompanied by high fever. Since I had no time to attend to the illness, I chose a two-week antibiotic treatment rather than homeopathy, with a feeling of great uncertainty. A short time later – although the reddening had already disappeared two days after taking the antibiotic – I began suffering from severe radicular neuralgic pains along the nervus ulnaris of the right arm. This illness was destined to impact me for years, until I undertook homeopathic treatment with a colleague in order to get well again.

The manifestations of a borreliosis infection are extremely idiosyncratic and multifarious. Pure pathognomonic symptoms tend to be rare, especially when the disease is advanced, which complicates the process of making a conventional diagnosis but has no impact on homeopathic treatment. Borreliosis possesses the special characteristic of being able to hide in the host organism in order to emerge when the body's defenses are compromised, manifesting itself again via constitutional, miasmatic weaknesses. So, illness symptoms and symptom complexes arise in various constellations as the expression of an

In the 1970s, Lyme borreliosis was recognized as an independent illness, triggering an almost hysterical reaction in the population. The subsequent vaccination campaign in Austria used the monstrous appearance of the tick to increase support for immunization against it.

copyright | Shutterstock / Cosmin Mancu





## BORRELIOSIS

organism's individual immune reaction, and these are difficult to classify from a conventional viewpoint. Homeopathy proves to be a tried-and-tested treatment method since it recognizes the individual, special symptom as the central expression of a generalized disturbance that is basically just reinforced by the pathogenic agent *Borrelia burgdorferi*, which simply raises its pathogenicity. There is much to learn about borreliosis. It eludes a conventional description of events, demanding a new, more modern perspective that is attuned to its specific nature.

### CASE 1: eight-year-old girl, erythema migrans, borreliosis

Tamara came without an appointment to my surgery, accompanied by her mother, when the circular mark on her right buttock became visible. According to her mother, the little girl has generally been rather unwell in that she has been more tired and listless than normal.

**Acute treatment:** the mother vehemently opposed antibiotic treatment. I asked her to repeat this in the presence of my assistant and write it down. I had never treated the girl. There was no time for comprehensive casetaking since she needed rapid acute treatment.

**Prescription:** 1 x 5 *Borrelia* 200C, then *Ledum* 30C dissolved in ¼ liter of water, to be taken in sips for three days, dissolved afresh each day

After three days, there was no visible change in the local symptoms. Yet, the little girl was evidently doing well and made a more lively general impression. I repeated a dose of *Borrelia* 200C and continued *Ledum* dissolved in water. Some days later, Tamara's mother phoned to say that the circle had started to steadily enlarge. I asked her to repeat *Borrelia* 200C, one dose if the circle stopped enlarging. Tamara was to continue taking dissolved *Ledum* in the meantime.

**Progress and comprehensive casetaking:** one month after the start of the erythema, Tamara returned for full casetaking. In the meantime, the circle had enlarged to almost the entire buttocks and seemed more pale than at the beginning. Although the initial treatment with the nosode and *Ledum* had stimulated the illness into a positive dynamic, so that the girl's general condition was completely unaffected, there were good reasons for more precise investigation. The propensity to fall ill from a pathogen always has a cause.

### CASE TAKING

**Tamara's situation:** Since moving from Lower Austria to Burgenland a year ago, Tamara had been displaying more noticeable problems than before. Above all she missed their old house, which was much nicer than the current one, and also her grandmother, who remained behind. She withdrew more

and more, and her appetite deteriorated noticeably. Later, she had a water wart (*molluscum contagiosum*) on the neck as well as eczema between the fingers of the left hand, although this spontaneously disappeared shortly afterwards.

**Family history:** Tamara has two older sisters, and together they are a good team. Although she was not a planned child, the pregnancy was without complication. Shortly before birth, her mother fell ill with flu and high fever. During the birth, she was thoroughly exhausted and weakened. There was placental retention and subsequent curettage. Completely unexpectedly, the mother's father died as a result of flu five weeks after the birth. Tamara's mother recovered only slowly from this phase of weakness.

Tamara was breastfed for a year and a half, and developed quickly and well. She scarcely crawled and learned to walk at the early age of ten months. She was able to talk early and she found it easy to learn. She made a rather serious impression and, indeed, she was very sensible and calm in all she did, not at all prepared to take risks. She could be stubborn, a know-all, occasionally refuse to do things but in general she was sociable. She tended to be sad, was easily moved, quick to cry, and suffered from homesickness. Fearful and easily started, she did not like being held high as a young child and did not like rollercoasters. She was afraid of the dark, being alone, and nightmares.

Tamara was not vaccinated. She suffered from a severe varicella infection.

Tamara's mother was caring and attentive. Her grandmother on the mother's side had an alcohol problem. Her father was a so-called "blue baby", as a result of which he was infection-prone and sickly. After myocarditis and an EBV infection, he suffered from chronic rheumatism, allergies, and asthma. The grandfather on the father's side died of cancer.

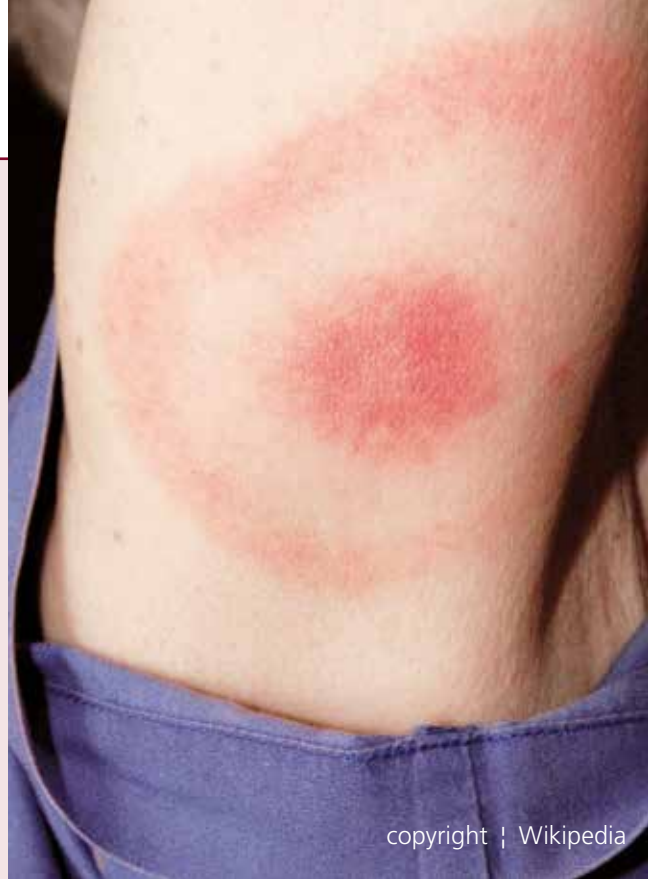**The patient's condition:** she is a tender, pale, dark-haired girl with large eyes. Sweat on the neck can lead to skin irritation. The holes of her ear-rings frequently become inflamed. She is sensitive to cold and is prone to frequent infections. Despite wearing a covering on her head, her ears easily become inflamed and she gets throat pains and mucous obstructions, worse in the morning. Aphthae in the mouth are not uncommon, worse after eating cheese. She eats little and is very picky. She loves sweet things, including strawberries and tomatoes. She dislikes beans and cabbage. She has a stool daily, often hard and painful. At night, she frequently awakes from a sleep filled with dreams, and has to get up to urinate. She also complains of growth pains.

**Prescription:** *Calcium silicata* M, one dose per day for two days

**Progress:** when she returned four weeks later, the erythema migrans had completely disappeared. There was merely a little

## LYME BORRELIOSIS

Lyme borreliosis has been recognized as a discrete illness since 1975. Despite intensive research, the scientific basis of the diagnosis and treatment is to this day inadequate. A negative serological finding does not exclude illness; on the other hand, a positive test only indicates that the patient had a borreliosis infection at some point in the past, not whether this is currently active or latent. In the early stage of infection, the appearance of erythema migrans indicates infection. However, since this is not mandatory, specific diagnosis – especially at an advanced stage – is laborious and unsatisfactory. The limited effect of antibiotic treatment of borreliosis infections is documented in many studies. Even following supposedly very effective antibiotic treatment, the pathogen can be observed to be further “cultivated” in the host organism. Borreliosis has the characteristic of evading the immune system when specific antibiotics are used. The pathogen uses an “escape mechanism” proved to exist as well in other bacteria. As borreliosis spreads in the organism, multi-organ and systemic disease can occur with an exceptionally wide array of pathological symptoms. The differential diagnosis to other forms



copyright | Wikipedia

of illness is extremely difficult. The diagnosis is therefore frequently made when all other diagnostic avenues have been exhausted. (Extract from the guidelines of the German Borreliosis Society: Diagnosis and Treatment of Lyme Borreliosis)

itching at the spot. Her sisters had fallen ill in the meantime with summer flu, which did not affect her. She seemed more stable and more open than before. She had brief nausea before falling asleep after taking the remedy on a number of evenings, otherwise there had been no signs of feeling unwell in the last few weeks. She was no longer afraid of the dark, generally expressed very few fears, no longer went to her parents at night, and had more stamina when hiking. The homesickness for her old house and her grandmother had diminished a little but was still present, and her appetite could have been better.

The water warts on the neck had clearly become enlarged, and the itchy eczema between her fingers had returned.

The rate of healing was acceptable. I repeated *Calcium silicata* once more.

**Follow-up:** a blood test at the Hygiene Institute in Vienna about two months after the treatment confirmed that she had overcome a borreliosis infection – she still had IgG antibodies. The successful homeopathic treatment was also confirmed. It was comparable to what might have been expected with antibiotic treatment.

## RENEWED CASE TAKING

A year and a half later, I saw Tamara again. Her mother complained about the girl's lack of strength. She was indeed quite pale and unmotivated. Although not definitely ill, she had various aches and pains. Her neck was often stiff and after school, she often had headaches in the forehead or neck pains. The balls of her feet were painful and she was also troubled by chronically inflamed pierced holes in her ears, in which she had had no studs for many years, and she also had “geographic tongue”. The suspicion that the borreliosis infection might be reawakening, this time involving the joints, greatly concerned Tamara's mother, prompting her to consult me again. She said that the water warts and the eczema between the fingers had completely disappeared after the treatment with *Calcareo silicata*. In the evening before going to sleep, she often had nausea, also complaining and nagging, and often saying how much she missed her grandmother.

The results of a blood test conducted straightaway confirmed once again that she had had a borreliosis infection but gave no clue as to whether the illness was active. There was also a slightly elevated ASL titer, otherwise everything was unremarkable. I decided not to do a joint puncture since the clinical picture



Marsh Labrador tea (*Ledum palustre*) is a plant species belonging to the Ericaceae family, commonly known as the Heath or Heather family. Subspecies occur all over the world. *Ledum palustre* has been used in herbal medicine. In homeopathy, it is given for insect bites including tick bites.

copyright | Jürgen Weiland

tended to indicate a pronounced weakness in her constitutional defenses and a liability to exhaustion – which in its pronounced form could be termed neurasthenia – rather than a severe infectious illness. Here, we can see the advantages of homeopathic treatment and viewpoint, in which specific symptoms can be individually situated within a person’s behavioral pattern, and this is precisely where and how the appropriate remedy can be recognized. The headaches were presumably tension headaches connected to mental stress. The other persistent complaints, especially the continuing longing for her grandmother as well as the now apparent weakness and poor motivation led me to prescribe *Acidum phosphoricum*.

**Prescription:** *Acidum phosphoricum* LM6, once a day

**Progress:** three weeks later, she was already feeling much better. All her physical complaints had improved. The joint complaints had entirely disappeared. She felt more active and happier. When asked about her homesickness for her old house, she replied spontaneously: “Now, I’m at home here in Burgenland!” I then gave her a single dose of *Acidum phosphoricum* MK and recommended that she continue to take the LM6 if the complaints returned, as required.

#### ANALYSIS

It was striking that there was an increased tendency to infections, followed by long-lasting weakness and a reduced ability to recuperate in Tamara’s family. Her father’s health was, from birth onwards, influenced by these factors, and her

mother had also developed a persistent state of weakness following the flu she had around the time of Tamara's birth. One grandfather died unexpectedly from flu and the other from cancer, and her grandmother suffered from alcoholism. Only her paternal grandmother, from whom she was now separated, was healthy.

Tamara's increased liability to fall ill with infectious disease followed by persistent weakness became apparent after the family's move, following the separation from her healthy grandmother and her familiar surroundings. This led her to feel deeply destabilized and this is precisely when the borreliosis infection occurred. As the illness progressed, *Calcarea silicata* and *Acidum phosphoricum* turned out to be the most suitable remedies to strengthen her constitution and her defenses.

---

**CASE 2: four-year-old girl, lymphadenosis benigna cutis (German name is B. Bäfverstedt), a borreliosis lymphoma**

---

The first time Lara comes to my practice, her right ear had been swollen and discolored red-blue for two weeks, although it did not hurt. She has pain in the joints of her lower body and along her shins, and for some time, her appetite has been poor. The clinical diagnosis is lymphadenosis benigna cutis (B. Bäfverstedt), which is a borreliosis lymphoma.

**Comments:** such pseudolymphomas usually arise reactively during the early stages of a borreliosis infection (stage I or II) around the area of the tick bite. There are soft, bulging, also nodule-like or grouped swellings on the skin with blue-red discoloration. The swellings are caused by lymphocytes in the skin. Typically these are found on the earlobes, neck, in the armpits, on the nipples, and genitals. Such skin lesions can form the center of erythema chronicum migrans.

**Acute treatment:** Lara evidently had a borreliosis infection in the first or second stage. Typical changes matching erythema migrans were at this time not present and had previously not been seen. There was no time for a thorough initial consultation as the little girl urgently needed immediate treatment. Her mother strictly refused antibiotic treatment, which is why she came to my homeopathic practice. I prescribed primarily *Ledum* 12D as a remedy that I have found effective in my practice for borreliosis infections during the initial stage, administered three times a day, plus *Borrelia* 200C once a day for the first three days. I also ordered a blood test for a more precise analysis.

**Prescription:** *Ledum* 12D and *Borrelia* 200C

**Progress and comprehensive casetaking:** three weeks after the start of treatment, Lara came once more, and now there

was enough time for a thorough casetaking. The girl had a slight cold. Her ear was still blue-red, also painful to the touch, and the joints were unchanged. The blood test indicated a raised level of borreliosis, type IgG. IgM-AK was not raised which, I did not know at the time, tends to show that the infection was no longer recent.

**CASETAKING**

Lara is a quiet and rather serious girl of late. She is sociable and likes sharing with her friends in kindergarten. The parent's separation a year and a half before affected her badly. She loves her father and misses him dearly. He was violent towards her mother and therefore he was ordered to leave by the police on several occasions. She also has a sister who is a year and a half younger, though she seems relatively unaffected by it all, which bothers her. Her mother says Lara is "wide awake and creative."

**Family history:** during the pregnancy, Lara's mother was extremely unsettled by the gynecologist's remark: "The fetus is too small." The birth of Lara in the 41st week of pregnancy lasted twenty-one hours. The opening phase was delayed and the APGAR score was 8 / 9 / 9. The child initially had torticollis, which responded well to physiotherapy. Her motor and linguistic development was rapid. Lara was very bright and defiant, preferring to cry alone if necessary. Even before the parents' separation, she tended to hyperventilate and suffer attacks of croup. Atopic dermatitis on the buttocks appeared a year after the parents separated, and was successfully treated with a fatty ointment. Last year, she had increasing joint pains and headaches. Lara was especially liable to colds, usually phlegmy. Her favorite food was French fries and she was afraid of storms.

The lymphoma and the joint pains were so far unchanged and her liability to infection returned in addition rather than replacing the joint pains.

**Prescription:** discontinue *Ledum*, *Tuberculinum Koch* 200C once a day for three days, followed by daily doses of *Silicea* LM3

**Progress:** just five days later, Lara developed a temperature of 40°C. On her own initiative, her mother gave her a few doses of *Belladonna* 30C and then continued with *Silicea*. She developed a severe cold and cough as well as acute otitis media on the right, where the lymphoma was also located. Her ear was massively swollen on the inside, discolored livid, and exceptionally sensitive to touch. With *Apis* 30C, there was rapid and convincing healing. The girl quickly felt healthy, seemed unusually wild and cheeky afterwards, perhaps even hyperactive. The lymphoma on the right ear disappeared during the acute episode! She continued to often complain of joint pains, which improved on motion, and was thirsty, drinking a large amount of cold water.

## BORRELIOSIS

**Prescription:** repeat *Tuberculinum* 200C and *Calcium phosphoricum* 30C, twice a week

**Follow-up:** after another four weeks, the previous nightly croup returned once, and this could be soothed with *Aconitum*. The joint pains disappeared. She became more assertive with her sister, and was better able to stand up for herself. She began, however, to cry more for her father. This prompted me to give her *Silicea* rather than *Calcium phosphoricum*. As a result, the eczema returned but then gradually healed. *Silicea*, in increasing potencies, has been helping Lara greatly for four years to become stronger and more stable. She has since remained free of all signs of borreliosis.

### ANALYSIS

As with Tamara (the first case), we can see in Lara's life issues of long-lasting, deep-seated uncertainty, which tended to repeatedly destabilize her, predisposing her to a tough and protracted borreliosis infection. The pregnancy was characterized by the uncertainty and fear of Lara's mother and the parental relationship was unstable, resulting in the loss of her father. Lara also found it hard to assert herself in relation to her sister.

The prescription of the *Borreliosis* nosode and *Ledum* in combination had the effect that the primarily inflexible symptoms became more reactive – they were effectively set in motion. Not until this stage began was I able to differentiate which symptoms were purely pathognomonic and which were constitutionally determined, hence the importance of selecting individual remedies attuned to the reaction pattern of the patient.

---

### CASE 3: twenty-six-year-old woman and her two-year-old son, erythema migrans, borreliosis

---

Desiree and Seraphin came to my practice with the same problem. Both had developed erythema migrans at exactly the same time: the mother had an erythema of 7 cm diameter on the left thigh, and her son had it on the left upper arm with a diameter of 4.3 cm.

**Acute treatment:** since the mother refused antibiotic treatment, I prescribed *Ledum* 12D, accompanied by *Borrelia* 200D, three doses at weekly intervals. At the check-up after three weeks, the erythema had disappeared in both patients. It had gradually faded during treatment, after initially expanding. Then, the sharp, ring-shaped edge began to break up.

**Previous history of the patients:** both were already known to me; mother and son had been in treatment for six months for a bonding problem. Desiree had had bonding and relationship problems for a long time due to her traumatic experiences in childhood. Since the birth of her son, she became much

more sensitized to these issues. She began with psychotherapy and, a few months later, also opted to start homeopathic treatment.

At the start of treatment, it was impossible for her to let the child leave her sight even for a moment, for fear that something would happen to him. Seraphin was also very attached to his mother. This symbiosis became more burdensome as he grew older, both for mother and son, and the father also needed a lot of patience to cope with it. Soon both mother and son were making progress with treatment. I will not go into the details of the remedies or the sequence, since it is not relevant for the treatment of the borreliosis. Accompanied by his father, Seraphin could soon visit the nursery, which he enjoyed a lot, and the dependency between him and his mother diminished. Desiree herself became more independent, which had become a major goal for her after she finally decided to leave her partner in order to live her own life. The little boy was, however, frequently taken to visit his father.

**Situation of mother and child:** just as the parents decided to separate, the erythema migrans – the visible sign of infection with Lyme borreliosis – developed in mother and child at the same time. The background to this infectious disease was therefore uncertainty in the patients' family relationships. The mother was generally unsettled and overextended by her motherhood and the relationship with her partner. Both seemed restless, and Seraphin was vigorously biting his fingernails. Since mother and son fell ill at the same time, I prescribed them both the same remedy to further support their constitutional defenses.

**Prescription:** *Zincum muriaticum* 30C, twice a week

**Progress and follow-up:** four months later, she came again, after both had stopped taking the remedy a few weeks earlier because they felt generally better – even the nail-biting had stopped. Seraphin suddenly developed several livid spots on various parts of his body, which soon disappeared again, or simply appeared somewhere else. I immediately viewed this unique skin reaction as related to the previous redness, which had now disappeared. Borreliosis is a true chameleon and can manifest again in quite a different form.

The mother was exceptionally well. She had obviously made the right decision to go her own way. Since the separation, she lived with Seraphin in a caravan at a campsite. The change of place and the fact that the mother was now doing a training course meant that the boy could not continue going to nursery. His daily schedule was rather stressful; he was in several places throughout the day and things became irregular for him. Everything had changed for him and he had to cope with a high degree of uncertainty.

I prescribed continuation of *Zincum muriaticum*, and the spots soon began to consistently recede.

For the last two years mother and son have not required medical treatment. Both are doing well.

### COMMENTS ON THE HOMEOPATHIC TREATMENT OF BORRELIOSIS INFECTION

In southern Austria, on the border to Slovenia, there is a very high incidence of borreliosis in the population. I have treated numerous infections and, due to this intensive encounter with the pathogen, I have developed a tried-and-tested approach to treatment.

**Comments on acute treatment:** borreliosis is generally transmitted by ticks. There is no absolutely safe method to avoid tick bites. If a tick has attached to the skin, it should be carefully removed by mechanical means. As an acute measure, I recommend the immediate application of blister ointment and an occlusion plaster dressing of the bite for 48 hours, as well as taking two or three individual doses of *Ledum* 12D.

If the skin looks normal after removing the dressing, nothing should be done at first. If, however, there is a sharply defined circular reddening (this can occur days and weeks later, or maybe not at all!), we can assume that there has been contact with the pathogen. In such cases, I commence treatment with *Ledum*, initially three doses a day, or at least until I can find an individual or constitutional remedy for the affected person. The intercurrent application of an occasional dose of the *Borreliosis* nosode in the potency 200D has also proved worthwhile. With this initial treatment of erythema migrans, there is generally an increase in the size, together with a paling and dissolution of the rim of the reddening. The dimension of the lesion should be regularly measured and tracked. The reddening can vary in an unpredictable way and, instead of quickly dissolving, it can spread to large areas of the entire skin and remain for months. As long as the process takes place on the skin surface, those affected generally feel healthy.

If an acute illness develops during this process, this should be treated primarily, with an acute remedy if needed, as long as the constitutional remedy cannot be recognized in the sum of observable symptoms. If no acute picture can be seen, the cause of the disturbance should be sought, since only a deeply acting treatment following the law of similars can bring borreliosis to a standstill.

The use of *Ledum palustre* at the beginning of the borreliosis infection has proved itself in my practice. It helps to reveal the masked pathogen and entice it to the surface. It promotes the illness process from the inside to the outside. Primarily rigid illness symptoms then become more reactive, which enables differentiation of whether they are purely pathognomonic or constitutional. *Ledum* enables us to distinguish the chaff from the wheat, so aiding individual remedy selection. In my research, I could establish that in several cases the use of *Ledum* on its own was sufficient to bring the infection to a prolonged halt. *Ledum palustre*, from the Ericaceae family, has a strong

relationship to the Iron series – this is a remedy that seeks to restore order.

### DESTABILIZATION AND LOSS OF EARLY SYSTEMS OF ORDER AS A REASON FOR ILLNESS WITH BORRELIOSIS

It is known that some people tend to be more easily affected by ticks than others, and there is a similar affinity for certain pathogens. Are there people who are potentially more liable to fall ill with Borreliosis or are there specific effects that promote such an infection?

While working with and analyzing the illness, I noticed some striking common factors. Complaints are frequently triggered by the loss of familiar certainty in the everyday life of those affected. Such factors include difficulties adapting after moving, destabilization due to loss of relationships, as well as loss of security in the areas of work and responsibilities. These people were effectively thrown off balance, stressed and unsettled, and infection occurred in such unstable situations.

### USE OF REMEDIES FROM THE THIRD AND FOURTH SERIES OF THE PERIODIC TABLE

In the three cases presented here, we can easily recognize this fundamental disturbance. This makes it understandable that remedies from the third and fourth series of the periodic table are frequently required. Here, we find remedies that help those people whose sense of order in life has been undermined, and here you can find those remedies that are able to heal damage to the basis of relationships, families and friendships.



#### CHRISTINA ARI

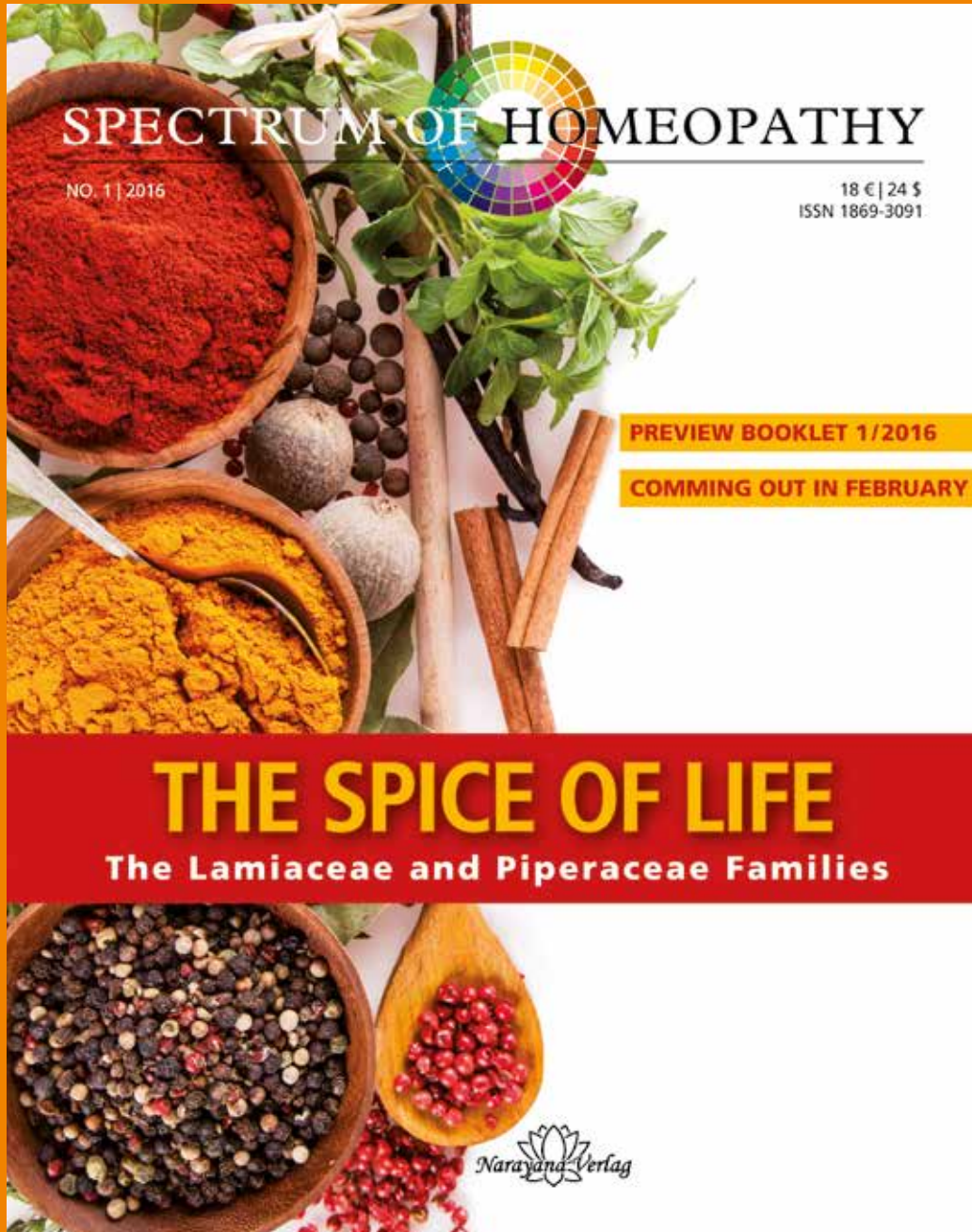
Studied Arts and medicine in Vienna, doctorate in 1983. Study of homeopathy since 1987 with Dorcsi, Mattitsch, Sankaran, and Scholten. She has her own practice since 1990 and works with the Austrian Society for Homeopathic Medicine (ÖGHM) since 1991. International presentations

with emphasis on Folliculinum, Hawaii remedies and stone remedies.

Publications in the HIÖ ("Homeopathy in Austria"), DocHom (Documenta Homeopathica) volume 30 on Pele's hair.

#### Contact:

christina.ari@gmx.at  
www.christina-ari.at



# SPECTRUM OF HOMEOPATHY

NO. 1 | 2016

18 € | 24 \$  
ISSN 1869-3091

PREVIEW BOOKLET 1/2016

COMING OUT IN FEBRUARY

## THE SPICE OF LIFE

The Lamiaceae and Piperaceae Families

  
Narayana Verlag

  
Narayana Verlag

Narayana Verlag GmbH

Blumenplatz 2 • 79400 Kandern, Germany • Phone: 00 49 (0)76 26 • 974 97 00  
Fax: 00 49 (0) 76 26 • 974 97 09 • [info@narayana-verlag.com](mailto:info@narayana-verlag.com) • [www.narayana-verlag.com](http://www.narayana-verlag.com)



Narayana Verlag

[Spectrum of Homeopathy 2015-3, Diagnosis Borreliosis - Mängel exemplar](#)

104 pages, booklet  
publication 2015



**order**

More books on homeopathy, alternative medicine and a healthy life [www.narayana-verlag.com](http://www.narayana-verlag.com)