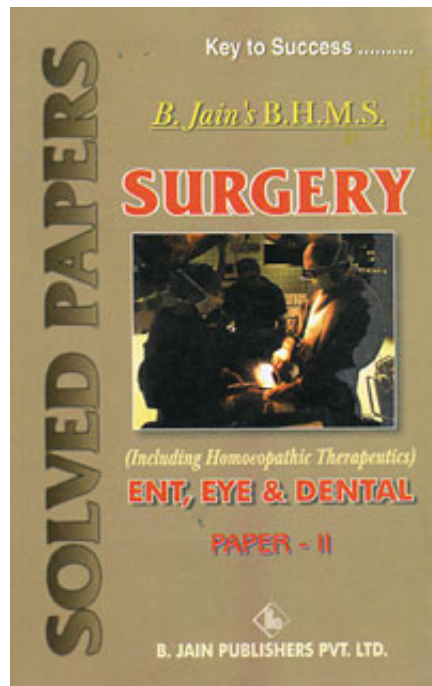


B. Jain

Surgery (Paper II)-Ent, Eye & Dental

Reading excerpt
[Surgery \(Paper II\)-Ent, Eye & Dental](#)
of [B. Jain](#)
Publisher: B. Jain



<http://www.narayana-verlag.com/b5590>

In the [Narayana webshop](#) you can find all english books on homeopathy, alternative medicine and a healthy life.

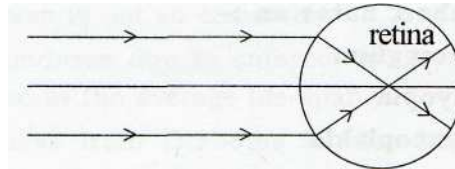
Copying excerpts is not permitted.
Narayana Verlag GmbH, Blumenplatz 2, D-79400 Kandern, Germany
Tel. +49 7626 9749 700
Email info@narayana-verlag.com
<http://www.narayana-verlag.com>



Treatment :

- (1) If Pterygium is stationary for atrophic stage and not much disfiguring, no treatment is necessary.
- (2) In progressive pterygium, the surgery is required.

(ii) Myopia : It is the error of refraction in which the parallel rays of light from infinity come to a focus in front of retina, when accommodation is at rest.

**Types of Myopia :**

- (1) Axial myopia
- (2) Curvature myopia
- (3) Index myopia

Clinical types :

- (i) Congenital myopia
- (ii) Simple myopia
- (iii) Pathological myopia

Ophthalmoscopic findings :

- (a) Myopic crescent.
- (b) Chorio-retinal atrophy.
- (c) Atrophic patches in the macula with sclerosis of choroidal vessels.
- (d) Ectasia of sclera at the posterior pole known as *posterior staphyloma*.

Symptoms of Myopia :

- Reduced visual acuity.
- But near objects seen clearly.

- The patient may complaint of seeing black spots floating in front of eyes due to vitreous opacities.

Treatment : By concave lens of suitable power.

(iii) Leucoplakia : Lucoplakia is the appearance of white patch usually on the cords and may look like a small prominent patch or a nodular plaque.

The lesion may be single or multiple. Leucoplakia is generally associated with hyperkeratosis.

- Causes**
- Idiopathic
 - Tobacco chewing

Prognosis - Leucoplakia is premalignant dysplasia.

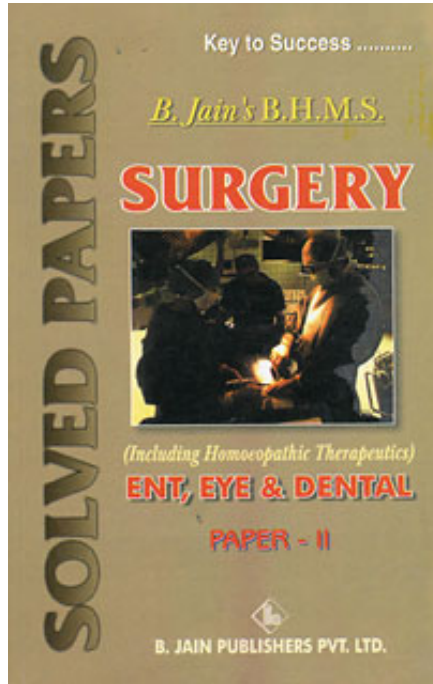
Treatment - Microsurgical excision.

(iv) Pyorrhoea : Pyorrhoea is an inflammatory infective condition of the gums and the membranes covering the teeth, in which there is a discharge of pus from teeth sockets or a collection of pus between the teeth and the gum margins.

Causes - The most frequent single cause of gingivitis (Pyorrhoea) is poor dental hygiene with a buildup of dental plaque around the base of the teeth. Other localised causes include tartar (calcified plaque), food traps between teeth and ill-fitting dental plates, caps or crowns. The gum inflammation that often develops during puberty or pregnancy is thought to be aggravated by hormonal factors. Gingivitis may also be a symptom of general illness (for example, in Diabetes Mellitus and Leukemia) and malnutrition (especially in scurvy and pellagra-Vitamin B₃ deficiency).

Complications :

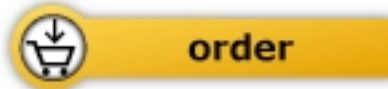- (1) Bleeding from gums.
- (2) An perverted taste due to pus in mouth.
- (3) Recession of gums and loosening of teeth.



B. Jain

[Surgery \(Paper II\)-Ent, Eye & Dental](#)

192 pages, pb
publication 2002



More books on homeopathy, alternative medicine and a healthy life www.narayana-verlag.com