

S.P. Dey

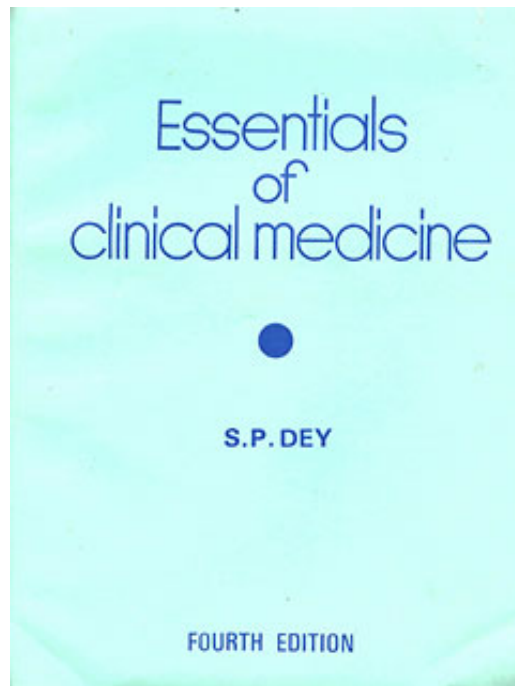
Essentials of Clinical Medicine

Leseprobe

[Essentials of Clinical Medicine](#)

von [S.P. Dey](#)

Herausgeber: Bhattacharya



<http://www.narayana-verlag.de/b5762>

Im [Narayana Webshop](#) finden Sie alle deutschen und englischen Bücher zu Homöopathie, Alternativmedizin und gesunder Lebensweise.

Das Kopieren der Leseproben ist nicht gestattet.
Narayana Verlag GmbH, Blumenplatz 2, D-79400 Kandern
Tel. +49 7626 9749 700
Email info@narayana-verlag.de
<http://www.narayana-verlag.de>



CHAPTER-III

THE RESPIRATORY SYSTEM

General survey :

The procedure is same as described under 'Case-taking' with special reference to the respiratory manifestations e.g. dyspnoea, cyanosis, type of breathing, rate and character of respiration etc.

Upper respiratory tract is examined first.

Inspection of the chest :

Carefully note the following :

(a) The shape of the chest (b) The type of breathing (c) The degree of expansion of the chest wall (movement of the chest wall during respiration) (d) The rate of respiration (e) The rhythm of respiration (f) The presence of prominent superficial veins on the chest wall, if any (g) Any growth or bulging (h) Any retraction of the chest wall e.g. in Pancoast's tumor, big cavities (i) Any winging of scapula etc.

THE SHAPE OF THE CHEST :

Normal : The normal shape of the chest is *elliptical* i.e. the transverse diameter is relatively longer than the antero-posterior diameter in 7:5 ratio.

Abnormal shapes of the chest: In normal persons the shape of the chest may sometimes be abnormal due to congenital deformity.

(a) **Alar chest or Pterygoid chest :** This type of chest is found in some cases of early pulmonary tuberculosis and in congenital mal-development. This has the following characteristics :

(i) Thorax is long and shallow (ii) *Intercostal spaces wide* (iii) Vertebral border of the Scapula prominent (iv) Shoulders depressed (v) *Sub-costal angle sharp*.

(b) **Flat chest :** This type of chest is most commonly met with in *pulmonary tuberculosis* and is characterised by the following :

(i) *The lateral diameter of the chest is much longer than the antero-posterior diameter* (ii) *The sternum is depressed and pushed nearer to the spine* (iii) *Intercostal spaces wide* (iv) Vertebral border of the scapula much more prominent (v) Shoulders depressed (vi) *Sub-costal angle sharp*.

(c) **Funnel-shaped chest or pectus excavatum :** This type of chest is found in *congenital deformity* or may result from obstruction in the bronchi in childhood and rarely found in cobblers. This is characterised by the following :

(i) Lower part of the sternum is depressed into a round hollow (ii) The chest looks like a funnel, (iii) **Prominent Costo-chondral junction.**

(d) **Barrel-shaped chest:** This is found in moderately advanced *bilateral emphysema* e.g. in chronic bronchitis, bronchial asthma etc. The characteristics are as follows :

(i) The chest is *rounded*, looking like a barrel (ii) Lateral expansion of the chest during inspiration is much less (iii) *The sternum is pushed forward and the spine backward* (iv) The ribs are straightened with approximation of the upper ones and separation of the lower ones (v) *The sub-costal angle is wider*. (vi) Supra clavicular fossa is full.

(e) **Pigeon-shaped chest or pectus carinatum :** This is found in *Rickets* and also as a *sequela* of *whooping cough*. The characteristics are as follows :

(i) *The chest is triangular* (ii) The ribs are straightened (iii) *Harrison's Sulcus present*—These are

two horizontal grooves along the lower part of the chest (iv) Antero-posterior diameter much increased due to unduly prominent sternum, (v) Beaded appearance at costo-chondral junction (Rickety-rosary).

(f) **Retraction of the chest wall** : This may be due to—(i) Bilateral cavitation of the lungs (ii) Fibrosis of the lungs (iii) Pleural effusion being absorbed, (iv) Collapse of lung.

(g) **Bulging of the chest wall**: There may be localised or generalised bulging of the chest wall. The causes are as follows :

(1) *Localised* : (i) Lung abscess (ii) Empyema necessitatis (iii) Pleural effusion (iv) Pneumothorax (v) New growths.

(2) *Generalised* : (i) Bilateral emphysema (ii) Emphysema.

THE TYPE OF BREATHING :

The type of breathing indicates the condition of the chest, the abdomen and the diaphragm. As such, it gives a primary idea as to the nature of disease the patient is suffering from.

Normal types of breathing :

(a) *Abdomino-thoracic* : This is found in male and children. The abdomen moves more than the thorax.

(b) **Thoracico-abdominal or thoracic** : The thorax moves more than the abdomen and is found in adult female.

Abnormal types of breathing :

(a) *Abdominal respiration* : Here only the abdomen moves with no or very slight movements of the thorax. This is found in : (i) Painful chest wall e.g. in lobar pneumonia, fracture of a rib, intercostal neuralgia, pleurisy, lung abscess etc. (ii) Deficient expansion of the chest e.g. in emphysema, pneumothorax, hydrothorax etc. (iii) Spasm or paralysis of the intercostal muscles fixing up the chest e.g. in acute anterior poliomyelitis, epilepsy etc. (iv) Stiffness of the chest wall due to calcification of costal cartilages.

(b) *Thoracic respiration* : Mostly the thorax moves with slight or no movement of the abdomen. This is found in : (i) *Acute inflammatory conditions in the abdomen* e.g. peritonitis, peptic perforation, liver abscess, haemorrhagic pancreatitis, intestinal obstruction etc. (ii) Paralysis of the diaphragm e.g. in Poliomyelitis, post-diphtheritic paralysis etc. (iii) Full term pregnancy.

THE DEGREE OF EXPANSION OF THE CHEST WALL :

(a) **Normal** : The expansion is equal on both the sides.

(b) **Abnormal** : If the expansion is poor and in-equal on either side of the chest, it is abnormal. This is found in emphysema, pleurisy, pleural effusion, empyema, hydrothorax, pneumothorax, lung abscess, collapse of the lungs, pneumonia etc.

THE RATE OF RESPIRATION :

Normal : The normal rate of respiration is 18 per minute in adult when the pulse rate is 72 per minute and temperature 98.4°F . Hence the normal pulse respiration ratio is (Pulse : Respiration = 4:1)

For every 1°F . rise of temperature, the pulse will increase by 10 and the respiration by 2.5 to 3 per minute. Roughly for 100°F temperature, the pulse rate is about 100 and the respiration 22 per minute.

Abnormal :

(a) *Tachypnoea*— *This means increased respiration rate in comparison to pulse and temperature. This is found in pneumonias, acute bronchitis, and any condition that leads to respiratory distress. Also seen in nervousness, fever, exertion etc.*

(b) *Bradypnoea* —This means slow respiration rate than normal. This is found in :

(i) Alcohol or opium poisoning (ii) Poisoning by chloroform (iii) Cerebral haemorrhage (iv) Meningitis (v) Brain tumor (vi) Uraemia (vii) Diabetic coma (viii) Epilepsy and hysteria (ix) Shock or collapse.

THE RHYTHM OF RESPIRATION :

(1) **Normal rhythm : The normal ratio of respiration is—
Inspiration : Expiration = 5:6.**

(2) **Abnormal or altered rhythm :**

(a) *Prolonged Inspiration* : This takes place due to narrowing of the air passages. This is found in :

(i) Laryngeal, tracheal or bronchial obstruction by foreign bodies (ii) Laryngeal diphtheria (iii) Acute broncho-pneumonia in children etc.

(b) *Prolonged expiration* : This takes place due to diminished elasticity of the lungs and narrowing of the bronchial tubes. This is found in: (i) Chronic bronchitis (ii) *Bronchial asthma* (iii) *Emphysema* (iv) Tropical eosinophilia (v) Early pulmonary tuberculosis etc.

(c) **Periodic breathing — It is of two types,**

(i) Regular or Cheyne - Stokes breathing and (ii) Irregular or Biot's breathing.

(i) Cheyne-Stokes breathing : This is a type of periodic breathing characterised by alternate phases of hyperpnoea and apnoea. There is sudden acceleration of the respiration with a series of inspiration gradually rising to its maximum and then it gradually falls to stop entirely for a period of about 30 seconds or more when it is followed by similar phases again. This is found in : (i) *Uraemia* (ii) *Diabetic coma* (iii) Heart block (iv) *Infarction of the heart* (v) Myocardial fibrosis with hypertension (vi) *Poisoning with opium* (vii) *Meningitis* (viii) *Cerebral haemorrhage* (ix) *Cerebral thrombosis* (x) *Cerebral embolism* (xi) *Typhoid state* (xii) Patent ductus arteriosus (xiii) Aortic regurgitation (xiv) Hydrocephalus (xv) Brain tumor.

N.B. —This type of breathing is normally found in certain *healthy children* and adult occasionally *during sleeping*.

(ii) Biot's breathing : This is a type of periodic breathing characterised by two or three quick deep and irregular inspirations followed by a period of apnoea—then it gradually falls. This type of breathing indicates serious condition of the patient and is found in : (i) *Cardiac failures* (ii) *Renal failure* (iii) *Tubercular meningitis* (iv) *Cerebro-vascular accident* etc.

(d) **Hyperpnoea : Here the depth of ventilation is increased and not the rate.**

(e) **Hyperventilation : Here rate and depth of respiration both are increased.**

(f) Short and interrupted breathing : The respiration is broken and short due to some painful condition in the chest. This is found in : (i) Acute dry pleurisy (ii) Fractured rib (iii) Hysteria etc.

(g) Stridulous breathing : The respiration makes a sound which resembles the sound produced by the friction of rough surfaces. This occurs due to laryngeal spasm or obstruction and is found in :

(i) Laryngismus stridulous (ii) Diphtheria (iii) Foreign bodies (iv) Strabismus (v) Tetanus etc.

(h) Stertorous breathing : This is characterised by a sonorous or snoring sound and is found in : (i) Paralysis of the soft palate (ii) Deep sleep (iii) Adenoid and enlarged tonsils (iv) Retro-pharyngeal abscess (v) Epilepsy (vi) *Diabetic coma* (vii) *Opium poisoning* (ix) *Alcohol poisoning* (x) *Cerebral haemorrhage, thrombosis, embolism* etc.

(i) Kussmaul's **breathing** : There is deep sighing, rapid breathing at a regular rate. It is found in uraemia, Diabetic Ketoacidosis, cerebral tumor, etc.

PRESENCE OF PROMINENT VEINS ON THE CHEST :

These are found in superior venacava and innominate vein obstruction.

Palpation of the chest :

Carefully note the following :

(i) *Vocal or tactile fremitus* -with its character and intensity (ii) *Tenderness of the chest wall* if any (iii) *Inspection findings* (vi) *Rhonchial fremitus* if present (vii) *Pleural friction* if present (viii) *Pulsation* on the chest wall if any. (ix) Position of the trachea (x) Position of the apex-beat.

VOCAL OR TACTILE FREMITUS :

Vocal fremitus is the vibration of the voice felt on palpation of the chest.

Process : Place the flat of the palm or the ulnar border of hand on the side of the chest, ask the patient to say 'one-one' or 'ninety-nine' and feel the vibration under the palm. Note the difference of vibration with the other side of the chest. (See fig. 6).

(a) **Normal** : This is comparatively increased on the right side especially in front of the chest as the right bronchus is wider and situated on a higher level than the left.

(b) **Vocal fremitus diminished** : This occurs in :

(i) Excessive accumulation of air in the lungs or pleurae e.g. Emphysema, Pneumothorax (ii) Accumulation of fluid inside the lungs or pleurae e.g. Hydrothorax, Pleural effusion, Empyema, Pyothorax, Haemothorax etc. (iii) Obstruction to the bronchus by a foreign body, new growth etc. (iv) Thickened pleurae due to old pleurisy (v) Thickened chest wall and fatty persons (physiological).

(c) **Vocal fremitus increased** : This occurs in :

(i) Consolidation of the lung (ii) Cavity of the lung—the cavity being superficial, big, empty and communicating with a patent bronchial tube (iii) Collapse of the lung with a patent bronchus (iv) Above the level of the fluid in case of pleural effusion (v) Thin chest wall and emaciated persons (Physiological).

TENDERNESS ON THE CHEST WALL :

This is usually localised and elicited in :

(i) Localised inflammatory condition e.g. abscess in the chest wall, mastitis etc. (ii) Acute dry pleurisy (iii) Intercostal neuralgia (iv) Intercostal myalgia or Pleurodynia (v) Empyema (vi) Fracture of the ribs or injury to the chest wall e.g. by a blow, fall etc. (vii) Osteo-periostitis of the ribs or sternum (viii) Pulmonary tuberculosis (ix) Herpes zoster (x) Pericarditis (xi) Hysteria (xii) Acute or chronic bronchitis (xiii) Emphysema (xiv) Diseases of the liver and gall bladder e.g. gall stone, liver abscess etc.

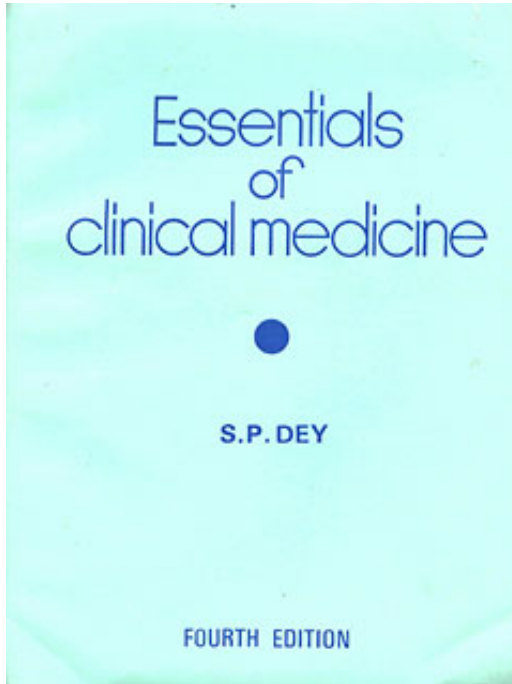
FLUCTUATION :

Localised fluctuation on any part of the chest may be elicited in (i) Abscess of the chest wall and (ii) Empyema necessitatis.

EXPANSION OF THE CHEST :

The expansion of the chest during inspiration is to be carefully noted and compared on either side.

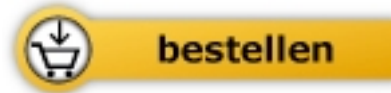
Process : Stand on one side of the patient, place the flat of the palms on either side of the chest keeping the thumb close together over the sternum on the middle line —then note the extent of gap in between the thumbs during inspiration. (See fig. 7).



S.P. Dey

[Essentials of Clinical Medicine](#)

190 Seiten, kart.



Mehr Bücher zu Homöopathie, Alternativmedizin und gesunder Lebensweise

www.narayana-verlag.de